



Role of Ilizarov external fixator in treatment of humeral non-union

Mohammed Anter Meselhy, Emad Sanad, Mamdoh Elkaramany

From the Benha Faculty Of Medicine, Orthopedic Surgery, Egypt

Treatment of non-union of the bone is a challenge, especially when the fracture is complicated by infection, angulation and translation, which is difficult to be managed by conventional methods.

Here, we discuss the technique and the results of treatment of humeral non-union by the Ilizarov method.

20 patients with 20 humeral shaft nonunions were treated by debridement and fixation following the Ilizarov method. The mean age of the patients was 35.05±11.48 years, there were 13 males and 7 females. The mean follow up period was 16.2 months. The mean time in the frame was 8.1 months. Bony union was achieved in all patients.

According to the A.S.A.M.I. Scale results were excellent in 13 patients (65%), good in 4 (20%), fair in 3 (15%). There were no poor results.

The Ilizarov method is effective in various types of humeral non-union, provided a good understanding of the fracture requirements.

Level of evidence : IV.

Keywords : Ilizarov ; humerus ; non-union.

The Ilizarov external fixator has proven its superiority in the treatment of different types of fracture non-union ; it offers rigid stability, possibility for bone transport and cyclic compression distraction which promotes bone healing at the fracture site (14).

In this study, we offer the ring fixator as a solution for both septic and aseptic types of humeral non-union ; we also discuss the technique and the outcome of this method in the treatment of humeral non-union.

MATERIALS AND METHODS

Between November 2011 and June 2015, 20 patients with 20 humeral shaft nonunions were treated by the Ilizarov method. The inclusion criteria were non-united humeral shaft fractures whether infected or not and including patients with severe nerve damage ; elderly and non-co-operative patients were excluded.

INTRODUCTION

Non-union is considered as one of the major complications of fracture treatment : in spite of major advancement in methods of fracture fixation, management of fracture non-union, especially when complicated by infection is still a challenging and difficult situation (13).

■ Mohammed Anter Meselhy,

■ Emad Sanad,

■ Mamdoh Elkaramany

Benha Faculty Of Medicine, Orthopedic Surgery, Egypt.

Correspondence : Mohammed Anter Meselhy, MD orthopedics, Associated professor of orthopedic surgery, Benha University, Orthopedic department, Benha University, Kafer el gazar, Banha, Qalyubia 13511 Egypt, Phone : +20 1007550217, Fax : +20 (13) 3227518.

E-mail : m.anteroof@yahoo.com

© 2020, Acta Orthopaedica Belgica.

Conflict of Interest : The authors declare that they have no conflict of interest.

Funding : there is no funding source.

In this multicentric study, all patients were treated by the same surgeon, using the same technique. All patients had a diaphyseal fracture of the humerus ; the mean age of the patients was 35.05 ± 11.48 years, range (19 to 58) years. There were 13 males and 7 females. The initial fracture was open in 5 patients, and closed in 15. The mean duration of fracture nonunion was 10.4 months (range from 7 to 20 months). The nonunion was complicated by infection in 14 patients. Sixteen had undergone previous surgery in an attempt to heal the nonunion, (1-3 previous surgeries). The right humerus was affected in 12 patients (the dominant side in 11) and the left in 8 (the dominant side in 1).

16 patients out of 20 were initially treated surgically by either plate and screws, an interlocking nail or a monoplaner external fixator, while 4 patients were managed conservatively by a hanging cast and u- shape slab (Table I).

Nonunion was found in the middle third of the humerus in 12 patients, in the proximal third in 5 and in the distal third in three. 8 patients had an angulation deformity at the non- union site while 3 patients had limb shortening range (1-2) cm .

Table I. — Distribution of the study group, according to type of initial fracture, method of initial treatment and number of previous surgeries

	Value (20) N(%)
Initial fracture	
Closed	15(75.0)
Open	5(25.0)
Initial ttt	
Conservative	4(20.0)
Ex Fix	3(15.0)
ILN	5(25.0)
Plate	8(40.0)
No of previous surgeries	
0	4(20.0)
1	7(35.0)
2	6(30.0)
3	3(15.0)

Preoperative assessment

All patients were carefully assessed preoperatively both clinically and radiologically, Associated problems like infection, deformity and joint stiffness were documented.

Preoperative shoulder stiffness was found in 5 cases and elbow stiffness in 9. Sympathetic dystrophy was present in 10 cases.

The radiological assessment of the site of non -union and nearby joints included plain X-rays (Antero-posterior and lateral views), computed tomography (C.T.), magnetic resonance image (M.R.I.) and a technetium-99m bone scan.

Laboratory investigations were done for all patients, including infection and culture and sensitivity tests for patients with an infected non -union.

According to the classification advocated by Ilizarov in 1998 (7), we had 15 patients with a hypertrophic non -union and 5 cases with an atrophic non -union. Six patients had an aseptic non- union while 14 were complicated by infection, of whom 3 presented with an actively draining sinus and 11 were closed.

Surgical technique

Patients were operated under general anesthesia. The patient was installed in the supine position, the affected limb resting on the operating table, allowing complete visualization of the whole arm with the image intensifier.

The whole affected upper limb was draped, including the hand, to allow visualization of finger movement during half pin and wire application.

Internal fixation hardware was removed through the previous incision, in both septic and aseptic non-union. Any necrotic bone proximal and distal to the fracture site was removed using a power saw until bleeding healthy surfaces were obtained and. The medullary canal was opened using a drill bit ; bone cortices were refreshed using a thin osteotome. Reduction of fracture was obtained by acute shortening and the fracture was provisionally held with K-wires.

The Ilizarov external fixator assembly was done from proximal to distal, arches and complete

Ilizarov rings were used ; the first arch was fixed to the humerus proximal to the deltoid muscle insertion using 5mm and 6mm half pins, the direction of half pins was from lateral to medial and from anterolateral and posterolateral to medial, engaging both cortices.

The 2nd level of fixation was below the level of the deltoid muscle insertion ; an arch or a complete Ilizarov ring was used with a sufficient clear zone at the medial and posterior aspect of the arm ; it was fixed to the humerus, above the fracture site, with 5 and 6 mm half pins from posterior to anterior and from posterolateral to anteromedial, away from the radial nerve.

The pins of the 3rd and 4th levels were inserted below the fracture site : complete one and half rings or complete one and 5/8th rings, open anteriorly, were used for fixation of the distal fragment.

Half pins of 5mm were inserted from lateral to medial and from posterior to anterior with the elbow in flexion during introduction of these pins in the distal 1/3 of the humerus.the K-wires for premenalry fixation of the fracture were removed (Fig. 1 A, B, C.).

1.8 mm wires were used in the distal construct especially in the intercondylar and supracondylar regions : at the lateral surface of the lateral condyle with the elbow flexed, one wire was inserted from posterolateral to anteromedial on the medial condyle, while the other wire was inserted transversely from the medial to the lateral epicondyle, with particular attention to eventual finger movement.

After tensioning of the wires, the proximal and distal constructs were connected using connecting rods. The wound was closed in layers with a drain (Table.II).

Postoperative treatment

On day 2, plain x-rays with anteroposterior and lateral views of the whole arm were taken to control the alignment and the nonunion site.

On day 3, the drain was removed, dressings were changed and an acute compression of the nonunion was done, if needed. Instructions for proper pin care and limb elevation were given.

The patient was discharged from the hospital on the 4th to the 6th postoperative day. IV antibiotics

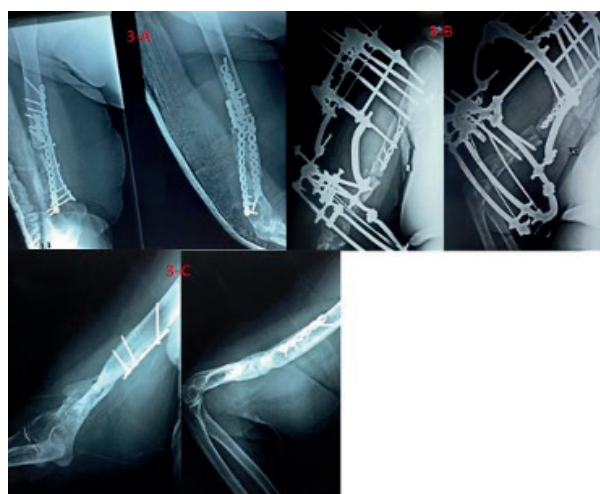


Fig. 1. — Intraoperative clinical photos showing the technique of debridement and Ilizarov application. A : bone after removal of hardware and debridement. B : bone with temporary fixation by K-wires. C : application of Ilizarov apparatus from proximal to distal.

Table II. — Distribution of the study group, according to nonunion type, site, presence of infective organism, number of previous operations and method of treatment by Ilizarov

	Value (20) N(%)
Nonunion type	
Mobile	5(25.0)
Stiff	15(75.0)
Infective organism	
None	6(30.0)
Gm -ve bacilli	1(5.0)
MRSA	5(25.0)
Pseudomonas	1(5.0)
Staph	7(35.0)
Site of nonunion	
Distal 1/3 diaphysis	3(15.0)
Middle 1/3 diaphysis	12(60.0)
Proximal 1/3 diaphysis	5(25.0)
Treatment method with Ilizarov	
Acute compression	10(50.0)
Compression-distraction	8(40.0)
Gradual compression	2(10.0)

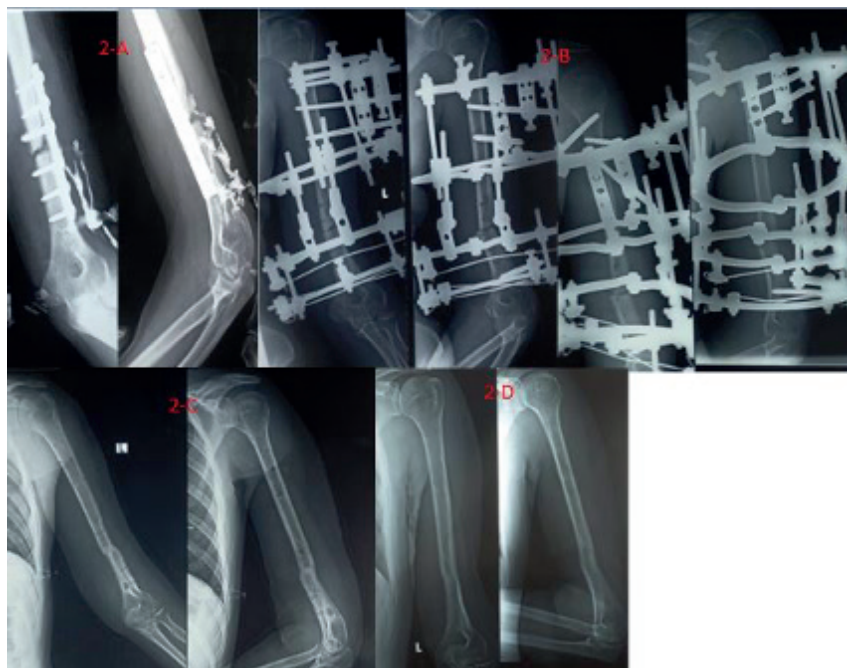

Fig. 2. — X-rays showing : A: pre-operative X-rays of infected non united fracture mid-shaft humerus fixed with a plate and screws. B : X-rays-after removal of internal fixation, sequestrectomy and Ilizarov application with acute compression. C & D : follow-up X-rays after Ilizarov removal.

and analgesics were administered during the hospital stay. The patient was discharged with oral antibiotics, according to cultures and sensitivity tests, oral non steroidal anti inflammatory drugs, anti oedema drugs like alpha chemotrypsin and neurotonics for two weeks.

The patients were followed in the out patient clinic on a two week basis to control the frame stability and pin sites and the radiographic progression of the bone union (Fig. 2A, B, 3A, B).

In some cases, cyclic compression distraction technique was applied as the patient moved the nuts for distraction and for compression by rate of half a turn each 12 hours, we began by distraction for 4 days, then compression for next 4 days then this cycle of repeated compression distraction was repeated for 5 cycles followed by acute compression at the nonunion site (Table.II).

After fracture consolidation, dynamization of the frame was done by loosening the nuts, then by decreasing the number of connecting rods between the proximal and distal constructs and finally

by removal of all connecting rods to be sure of complete union.

Removal of the apparatus was done in the operation theatre under general anesthesia.

Physiotherapy and rehabilitation

Post-operative phases

Phase 1 (Inpatient ; postoperative day 1-7)

Independent mobilization and transfers.

Range of motion exercises of the joints above and below the frame within normal ranges or at least to the ranges measured in the operating room after application of the Ilizarov frame.

Stretching exercises and functional loading activities for home program.

Phase 2 (Outpatient).

Maintenance of range of motion of joints above and below the fixator.

Functional loading activities advanced to incorporate closed kinematic chain strengthening .



Fig. 3. — X-rays showing :A : non united fracture mid-shaft humerus fixed by double plating with fixation failure. B : Ilizarov application after removal of plates and screws. C : follow-up X-rays after apparatus removal.

Phase 3 (Outpatient ; fixator removed)

- (1) Mobility of any joints incorporated into the fixator restored to within normal limits.
- (2) Strengthening increased to a normal level with closed kinematic chain activities.

RESULTS

Data management

The clinical data were recorded on a report form. These data were tabulated and analyzed using the computer program SPSS (Statistical package for social science) version 20 to obtain :

Descriptive data

Descriptive statistics were calculated from the data in the form of : mean and standard deviation (\pm SD) for quantitative data and frequency and distribution for qualitative data

Analytic statistics

In the statistical comparison between the different groups the significance of difference was tested using one of the following tests :

Paired t test and Willcoxon test (Ztest) : Used to compare the mean of variables in different time periods of quantitative data of parametric

Table III. — Distribution of the study group, according to time before Ilizaov, Ilizarov duration and duration of follow-up

	Value (20) Mean \pm SD (range)
Time before Ilizarov	12.65 \pm 3.91 (7-20)
Ilizarov duration	8.1 \pm 2.34 (5-12)
Duration of follow up	16.2 \pm 4.35 (10-24)

Table IV. — Bone results

Bone results	Number	Percentage
Excellent	13	65%
Good	4	20%
Fair	3	15%
Poor	0	0%

and non-parametric tests respectively. Inter-group comparison of categorical data was performed using McNemar test.

A P value <0.05 was considered statistically significant (*) and >0.05 statistically insignificant ; P value <0.01 was considered highly significant (**) in all analyses.

The mean time between injury and the application of the frame was 12.65 (SD 3.91-range 7-20) months. The mean follow up period was 16.2 (SD 4.35-range 10-24) months. The mean time in the frame was 8.1 (SD 2.34-range, 5-12) months. Bony union was achieved in all patients.(Fig. 2C,2D,3C).

The ASAMI (Association for the Study and Application of the Method of Ilizarov) protocol, 1991”1” was used to standardize the side effects and complications.(Table III)

According to this scale, the bone results were excellent in 13 patients (65%), good in 4 (20%), fair in 3 (15%) and poor in none. (Table IV)

Residual deformity was found in 5 cases (25%), the deformity being less than 7 degrees of the normal anatomical axis. 3 patients (15%) had a significant shortening > 2.5 cm. Superficial type pin tract, infection around wires or pins was present in all 20 patients.

Table V. — Functional results

The result obtained	Number	Percentage
Excellent	12	60%
Good	4	20%
Fair	2	10%
Poor	2	10%

Frame adjustment was needed in one patient. Psychological troubles were observed in 5 patients in the form of depression and anxiety treated with psychotropic medication.

The functional results were excellent in 12 patients (60%), good in 4 (20%), fair in 2 (10%) and poor in 2 patients (10%) (Table V & VI).

Table VI. — Comparison of elbow ROM arc, shoulder abduction, DASH score and VAS score preoperative and postoperative

	Pre op Mean \pm SD	Post op Mean \pm SD	Test	P value
Elbow ROM arc	97.0 \pm 31.68	106.75 \pm 30.49	Paired t= 1.93	0.068
Shoulder abduction	127.25 \pm 36.47	123.5 \pm 22.07	Paired t= 0.60	0.55
DASH	29.27 \pm 11.52	7.54 \pm 13.69	Z= 3.92	0.001**
VAS	7.15 \pm 1.46	1.9 \pm 2.1	Z= 3.94	0.001**

Table VII. — the comparison between the current study and other similar studies.

	Manish et al 2010 (9)	Das et al 2005 (4)	Patel et al 2000 (12)	Our series
Age (mean) years	39.4 (18-57)	24-65	36-65	35.05 (19-58)
No. of patients	19	11	16	20
No. of previous operations (mean)	1.7	3	2.6	1.95
Follow up (Mean) Months	24-126	9-22	31	16.2
Time to Ilizarov (Mean) months	10.4	9.65	9.5	12.65
Ilizarov duration	6.4	7.2	4	8.1
Union	100 %	100%	98%	100%
Eradication of Infection	100 %	100%	95%	70%
Complications	87	68	71	65 complications
Bone results Excellent	94.73%	90.9%	92%	65%
Good	5.26%	9.09%	4%	20%
Fair	0%	0%	4%	15%
Poor	0%	0%	0%	0%
<i>Functional results</i>				
Excellent	73.68%	63.63%	15%	60%
Good	21.05%	0%	45%	20%
Fair	5.26%	9.09%	15%	10%
Poor	0%	0%	20%	10

DISCUSSION

One of the most important factors in fracture union is the preservation of local blood supply of the bone fragments : in the humerus wide surgical exposure can destroy the nutrient vessels between the middle and lower thirds of the bone (11,15).

Revision surgeries by conventional methods of internal fixation are technically difficult ; most of humeral nonunions are displaced and angulated with or without bone loss. Moreover, these methods are contraindicated when the fracture is complicated by infection (3).

The Ilizarov external fixator offers two antagonist mechanisms in enhancement of fracture union : rigid static fixation as a scaffold and dynamic fixation when compression distraction is needed at the fracture site.

Circular fixation carries many advantages : the ability to correct angulation, the possibility of acute or gradual bone translation, the ability to restore bone length through distraction osteogenesis, enhancement of local blood supply by distraction and increasing the osteogenesis through compression ; moreover insertion of transosseous wires, especially in osteoporotic bone, allows rigid stability (7,8,11,16).

In case of infected non- union, the Ilizarov external fixator proved to be superior, offering rigid fixation, preservation of local blood supply, ability for bone transport after corticotomy and the ability to perform repeated compression distraction cycles at the nonunion site (2,5,6).

Ring et.al. have documented loss of humeral length of an average of 2.4cm (range1-3.5)cm, in their study group of humeral nonunion treated by a bridging plate and autogenous iliac bone graft (13).

Lammens et al. have reported bone consolidation in 28 out of 30 patients with humeral nonunion after an average of 4.5 months, they had however 4 patients with a refracture after frame removal. In our series union was achieved after an average period of 5 months and there was no refractures following frame removal (10).

In the current study we discuss the outcome and the technique of treatment of 20 cases of different types of humeral nonunion with the Ilizarov external

fixator ; the anatomical and functional results were compared with the results of other similar studies ; our results were satisfactory.(Table.VII)

CONCLUSION

We hypothesized that the Ilizarov technique is effective in the treatment of humeral nonunion, as regards bone healing and eradication of infection with an acceptable rate of complications.

The study was approved by ethical committee of Benha university and were in accordance with the ethical standards of the institutional and national research committee and with the 1964 Helsinki declaration and its later amendments or comparable ethical standards.

Acknowledgement

To our professor Gammal Ahmed Hosny, who had helped us to perform this work. and professor Emad eldin Essmat for his support. Ethical approval.

Informed consent

All patients signed an informed consent after clear explanation of the surgical procedure.

REFERENCES

1. **ASAMI Group : Editors A Bianchi Maiocchi and J. Aronson.** Operative Principles of Ilizarov Medi Surgical Video, Milano, 1991.
2. **Catagni M.** Classification and Treatment of Nonunion, in : Maiocchi, A.B., Aronson, J., Eds. Operative Principles of Ilizarov : Fracture Treatment – Nonunion – Osteomyelitis – Lengthening – Deformity correction, ASAMI group. Williams and Wilkins. 1991a, 190-198.
3. **Cierny, George III, Mader, Jon T, Penninck and Johan J.** A Clinical Staging System for Adult Osteomyelitis. *Clin Orthop Rel Res* : 2003 ; 7-24.
4. **Das DK, Paul AK, Datta DC, Biswas D, Ahmed SAM, Hashem MA.** Nonunion of adult humerus fracture management using the Ilizarov external fixator. *Faridpur med. coll.j.* 2005 ; 67-72.
5. **Danis A.** Mechanism of bone lengthening by the Ilizarov technique. *Bull MemAcad R Med Belg.*2001 ; 156 :107-12.

6. **Hosny GA and Fadel M.** Ilizarov External Fixator for Open Fractures of the Tibial Shaft. *Int Orthop* (SICOT),2003.
7. **Ilizarov GA.** Transosseous osteosynthesis. New York : Springer-Verlag, 1998.
8. **Ilizarov GA.** Clinical Application of the Tension-Stress Effect for Limb Lengthening. *Clin Orthop Rel Res* 1990 ; 250 : 8-26.
9. **Kiran Manish, Jee Rabi.** Ilizarov method for treatment of nonunion of diaphyseal fractures of humerus. *Indian J Orthop* 2010 ; 44 : 444-447.
10. **Lammens J, Bauduin G, Driesen R, Moens P, Stuyck J, Smet LD and Fabry G.** Treatment of non-union of the humerus using the Ilizarov external fixator. *Clin Orthop* 1998 ; 223-230.
11. **Modabber MR and Jupiter JB.** Operative management of diaphyseal fractures of the humerus. Plate versus nail. *Clin Orthop* 1998 ; 93-104.
12. **Patel VR, Menon DK, Pool RD and Simonis RB.** Nonunion of the humerus after failure of surgical treatment, management using Ilizarov external fixator. *J Bone Joint Surg [Br]* 2000 ; 977-83.
13. **Ring D, Jupiter JB, Quintero J, Sanders RA and Marti RK.** Atrophic ununited diaphyseal fractures of the humerus with a bony defect. *J Bone Joint Surg [Br]*2000 ; 867-871.
14. **Rose RC and Palmer WO.** The Ilizarov method in infected nonunion of long bones. *West Indian Med J* 2007 ; 3 : 246-251.
15. **Rosen H.** The treatment of nonunions and pseudarthroses of the humeral shaft. *Orthop Clin North Am* 1990 ; 21 : 725-742 .
16. **Saleh M and Royston S.** Management of nonunion of fractures by distraction with correction of angulation and shortening. *J Bone Joint Surg* 1996 ; 105-109.